

Health Monitoring of Fetal Ultrasound Image Using Active Contour Models

Ahmad Puji Santoso

Informatic and Computer Departement
Electronic Engineering Polytechnic Institute of Surabaya
Surabaya-East Java, Indonesia
ahmadpuji@ce.student.pens.ac.id

Riyanto Sigit, S.T., M.Kom, Ph.D

Informatic and Computer Departement
Electronic Engineering Polytechnic Institute of Surabaya
Surabaya-East Java, Indonesia
riyanto@pens.ac.id

Abstract—Analysis of the health condition of the fetus on ultrasound is needed by medical personnel as well as of pregnant women who are pregnant. At a young age the pregnancy is still a great time to do the analysis on the condition of the baby in the womb. But most of this process can only be done by experts, namely medical personnel. It is necessary for a segmentation process on the results of the ultrasound image processing that aims to help medical personnel, patients are pregnant women and the general public to determine how the development of the fetus to grow healthy or whether there is any abnormality. The parameters which will be used as the basis for determining the level of health of the fetus in early pregnancy, the length of the fetus (Crown Rump Length) and the gestational sac diameter (gestational sac). The parameters are expected to be visible after the ultrasound image through a phase of segmentation by using Active Contour Models. This method uses the principle of minimizing the energy to detect specific feature in the image.

Keywords—Ultrasound, Fetus, Active Contour Models

I. INTRODUCTION

Analysis of fetal health conditions on the image of ultrasound is needed by medical personnel and pregnant women who are pregnant. At a young gestational age fetal analysis is important to determine the location of pregnancy, fetal age, fetal number, screening of the first congenital defects and abnormalities that may occur in the fetus [1]. Because the advantages of ultrasound image processing are safe for patients, this imaging technique is more interesting than other retrieval techniques. But the processing is often found the noise, low contrast, and poor image quality, making it difficult for medical personnel themselves to perform the analysis process. This segmentation can be done to group and simplify the process of fetal ultrasound image processing analysis.

Segmentation is an important part of image processing in health sector. Segmentation has been widely applied to ultrasound image processing with various methods where there are deficiencies and advantages. So far, various image segmentations have been performed using methods such as Watershed [2], Clustering, Active Contour [3], Edge Detection Algorithms [4] and so on.

In this segmentation research on ultrasound image to determine the health of the fetus will be performed. Prior to

segmentation process, preprocessing should be done first to improve the quality of ultrasound image, by increasing contrast and eliminating noise. Segmentation method used is Active Contour Models method. This method performs the process by collecting several points which are then connected and controlled by a line. The output of the segmentation process is a fetal ultrasound image where the fetus and gestational sac have been separated from the background object. Furthermore, long measurements were taken. With this method is expected to lower the quality of ultrasound image processing can be improved so as to facilitate the determination of fetal health.

II. THEORY SUPPORT

A. Ultrasonography

Medical ultrasound (sonography) is an ultrasound imaging diagnostic technique used to image internal organs and muscles, their size, structure, and pathology wounds, making this technique useful for examining organs. Obstetric sonography is commonly used during pregnancy. The choice of frequency determines the resolution of the image and the penetration into the patient's body. Sonographic diagnostics generally operate at frequencies from 2 to 13 megahertz. While in physics the term "ultra sound" includes all acoustic energy with a frequency above human hearing (20,000 Hertz), its general use in medical imaging involves a cluster of frequencies hundreds of times higher. Digital image processing is one of the areas in the computer world that began to grow since humans understand that computers are not only able to handle text data, but also image data. Image processing terminology is used.

These digital biomedical image processing processes generally aim to detect objects and to perform further measurements and then be used to support the diagnostic process. For this purpose, the type of image processing that is often required in this application is the process of pre-processing as well as the classification and image segmentation. Pre-processing process is often referred to as low-level processing. At that stage, it is usually necessary to improve the quality of the image, as well as the process of detecting the sides or lines of boundaries between different objects, such as between bone and tissue or between healthy

tissue and diseased tissue. Image analysis in the form of detection or identification of objects can be done through the process of image classification process to several objects and the process of comparison between the object characteristics observed with knowledge of the familiar object characteristics. The process of diagnosis based on the results of this image processing is not enough just to see the difference in the gray level of the image elements between the sick and healthy parts, but also through the differentiation of the size of body parts observed with the body parts under normal circumstances. The measurement of the magnitude of an object in the image can be done by counting the number of pixels which states the gray level of the category of the object.

This sonography shows the image of the head of a fetus in the womb. In the case of pregnancy, Ultrasound (USG) is used by a gynecologist (DSOG) to estimate the gestational age and estimate the day of delivery. In the world of medicine is widely, ultrasound (ultrasonography) is used as a tool for diagnosis of body parts that are awakened from the fluid.

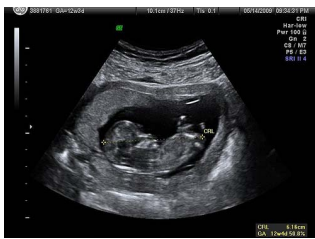

Figure 2.1 Fetal Ultrasound Image

B. Determinants of Fetal Health

Fetal length measurements (Crown Rump Length, CRL) and gestational sac (GS) diameter have been widely used to determine gestational age and to predict the state of a pregnancy, whether the fetus in it will grow healthy or miscarriage. This measurement is well done for gestational age between 6 to 10 weeks.

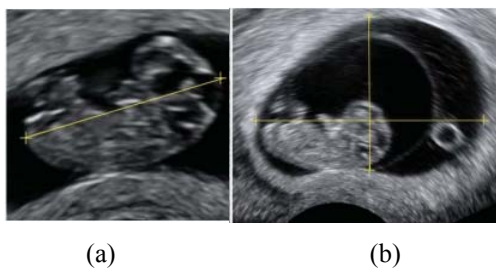


Fig 2.2 Illustration of CRL and GS Measurements
(A) fetal measurement (b) measurement of gestational sac

C. Crown Rump Length (CRL)

CRL is the longest fetal size from head to butt without including limbs. CRL can be measured at 6-7 weeks gestation. CRL is the most accurate measurement method in determining gestational age in early pregnancy with error ± 3 days only. The results of CRL measurements are not affected by maternal age, height, parity or race. However, the more gestational age, the fetus will grow longer so it tends to bend and do not depict

the actual length. Therefore, CRL measurements are primarily indicated in 7-10 weeks of pregnancy with errors ± 3 days. After 10 weeks pregnancy the fetus will become more curved so that its accuracy decreases.

Table 2.1 Estimated Pregnancy Age of Fetal Length

GS	PA	GS	PA	GS	PA
0,2	5,7	1,2	7,4	2,2	8,9
0,3	5,9	1,3	7,5	2,3	9,0
0,4	6,1	1,4	7,7	2,4	9,1
0,5	6,2	1,5	7,9	2,5	9,2
0,6	6,4	1,6	8,0	2,6	9,4
0,7	6,6	1,7	8,1	2,7	9,5
0,8	6,7	1,8	8,3	2,8	9,6
0,9	6,9	1,9	8,4	2,9	9,7
1,0	7,2	2,0	8,6	3,0	9,9
1,1	7,2	2,1	8,7	3,1	10,0

Information:

PA : Pregnancy Age in weeks

CRL : Crown Rump Length

D. Gestational Sac (GS)

Gestational Sac or gestational sac begins to be seen with ultrasound devices at 4-5 weeks gestation. Determination of gestational age by measuring the gestational sac results is almost near the age of pregnancy by counting from the last menstruation.

Table 2.1 Estimated Pregnancy Age of Fetal Length

GS	PA	GS	PA	GS	PA
1,6	5,9	2,6	7,3	3,6	8,8
1,7	6,0	2,7	7,5	3,7	8,9
1,8	6,2	2,8	7,6	3,8	9,0
1,9	6,3	2,9	7,8	3,9	9,2
2,0	6,5	3,0	7,9	4,0	9,3
2,1	6,6	3,1	8,0	4,1	9,5
2,2	6,8	3,2	8,2	4,2	9,6
2,3	6,9	3,3	8,3	4,3	9,7
2,4	7,0	3,4	8,5	4,4	9,9
2,5	7,2	3,5	8,6	4,5	10,0

Information:

PA : Pregnancy Age in weeks

GS : Pregnancy sac (Gestational sac) in cm

E. Image Segmentation

Segmentation process is a process to separate between one object with another object or between objects with background contained in an image. With the process of segmentation, each object in the image can be taken individually so it can be used as input for other processes. Given the importance of the segmentation process, it takes a segmentation method that can

perform accurate object separation. Inaccuracy of the segmentation process may lead to subsequent inaccuracies. In this final project method used for segmentation process that is Active Contour Models.

F. Active Contour Models

The concept of Active contours models was first introduced in 1987 and later developed by various researchers. Active contour uses the principle of minimizing energy that detects certain features in the image, is a flexible curve (surface) that can adapt dynamically to the desired edge (edge) or object in the image (can be used for object segmentation automatically). This system consists of a set of interconnected and controlled points by a straight line, as shown in Figure 2.3, Active contour is described as a number of consecutive controlled points with each other. The determination of objects in the image through active contour is an interactive process. Users should estimate the initial contour, as shown in Figure 2.3., The specified contour is almost close to the object feature form. Furthermore, contour will be attracted towards the feature in the image because of the influence of internal energy that produces the image.

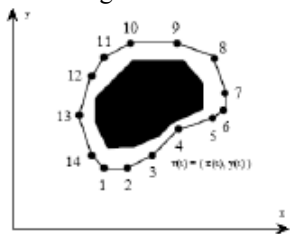


Fig 2.3. Basic Form of Active Contour

The active contour parameter for a set of controlled coordinate points in contour can be defined as follows :

$$\vec{v}(s) = (\vec{x}(s), \vec{y}(s)) \dots\dots\dots(1)$$

Where x (s) and y (s) are the coordinates x and y on the contour and s is the normalization index of the control point. The energy function described active contour consists of two components, namely internal energy and external energy. The internal force creates a compact curve (elastic force) and the limits turn very sharply (flexural force). External forces tend to make the curve move toward the boundary of the object. The internal energy as a sum of elastic energy and flexibility can be expressed as follows :

$$E_{int} = E_{elastic} + E_{bend} = \alpha(s) \left| \frac{dv}{ds} \right| + \beta(s) \left| \frac{d^2v}{ds^2} \right| \dots\dots\dots(2)$$

The energy of elasticity and flexibility can be defined as follows :

$$E_{elastic} = \dots\dots\dots(3)$$

And

$$E_{bend} = \int \beta(v(s-1) - v(s) + v(s+1)) . ds \dots\dots\dots(4)$$

The energy minimization function can be shown as follows :

$$E_{snake} = \int E_{snake}(v(s)) . ds = \int \{ E_{int}(v(s)) + E_{image}(v(s)) + E_{con}(v(s)) \} . ds \dots\dots\dots(5)$$

Where E_{int} is the internal energy of the curve, E_{image} is the energy of the image, and E_{con} is the external energy. After the segmentation is done the accuracy test by comparing the image that is segmented manually with the image of the program segmentation results.

G. Region Filtering

Region filtering is used to remove contours away from center points and small contours by estimating the area of each contour. Contours on fetal cavity images are selected only on the inner contours only. Contours with an area smaller than the specified limit value are removed (not considered) from the contour. The value of the boundary of the contour and radius has been determined based on the radius that has been selected. Figure 2.4 below is an example of region filtering application.




Fig 2.4 Example of application of region filtering (A) edge detection results (b) removes contours away from the center (c) removes small contours

H. Integral Projection

Integral projection is a method used to search the region or location of an object. This method can be used to detect the boundaries of different image areas, so that can be searched the location of faces and feature-feature. This method can also be called the integral row and column of pixels, since this integral adds pixels per row and pixels per column. From this method it will be easy to find the area where the object is needed.

$$HIP = \sum_{j=1}^n f(i, j) \dots\dots\dots(2.13)$$

$$VIP = \sum_{i=1}^n f(i, j) \dots\dots\dots(2.14)$$

Fig 2.5 below is an illustration of the integral projection method.

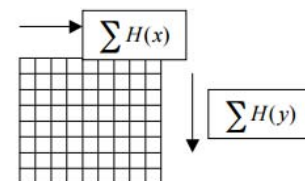


Fig 2.5 Illustration of integral projection method

III. DESIGNING AND MANUFACTURING SYSTEMS

A. Design Systems

This section represents the design and manufacture of the system used. Here is a system flow diagram used in the final project implementation :

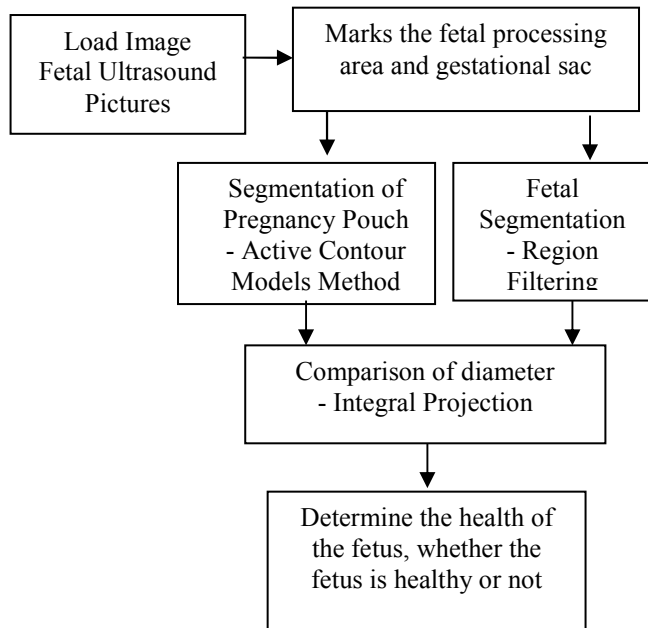


Fig 3.1 System Flow Chart

B. Load Image

In this research the input used is offline image from fetal ultrasound image obtained from Rumah Aura Syifa, Kediri. The fetus image used is 6 to 10 weeks old. The image used is .bmp. Here is a snippet of fetal ultrasound image file reading.

C. Segmentation of Pregnancy Pouch

The next stage is to segment to detect the pregnancy sac on the fetal ultrasound image. The method used is Active Contour Models method.

The concept of active contours models uses the principle of minimizing energy that detects certain features in an image, a flexible surface curve that can adapt dynamically to the desired edge (edge) or object in the image (can be used for object segmentation automatically). This system consists of a set of points that are interconnected and controlled by a straight line. Active contour is described as a number of controlled points sequentially to each other. In this study the area to be segmented will be found contour by determining the value of parameters used manually.

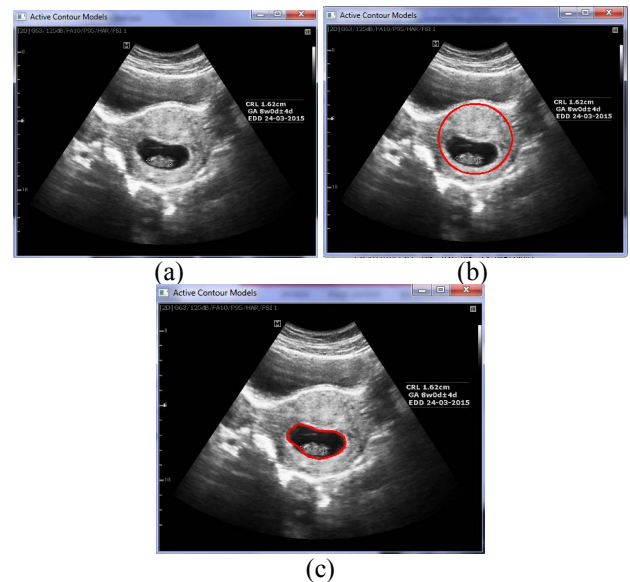


Fig 3.2 Examples of active contour models segmentation (a) original fetal image, (b) markers in active contour models, and (c) segmentation of active contour models.

D. Fetal Segmentation

In addition to the sac of pregnancy, other objects that need to be separated from the background of the fetus. Fetal segmentation is performed using triangle method, where this method consists of Region Filtering, Crosses and Triangle Equations. Region filtering is used to remove contours outside the unintended fetal area. And the crossing line is used to optimize contour numbers by clarifying and obscuring the contour to be almost identical to the actual contours. Then a triangular equation is used to connect the disconnected point on the fetus.

E. Region Filtering

Region filtering is used to remove contours away from the center by estimating the area of each contour. Contours on selected fetal images only on the inner contours only. Contours with values greater than predetermined values are discarded (not considered) from contours. The value of the boundary of the contour and radius has been determined based on the radius that has been selected with mouse click.

F. Integral projection

Integral projection is a method used to search the region or location of an object. This method can be used to detect the boundaries of different image areas, so that can be searched the location of faces and feature-feature. This method can also be called the integral row and column of pixels, since this integral adds pixels per row and pixels per column. The following is the integral projection equation used.

$$\begin{aligned}
 \text{HIP} &= \sum_{i=1}^n f(i, j) \\
 \text{VIP} &= \sum_{j=1}^m f(i, j)
 \end{aligned}$$

In this final project, integral projection is used to compare the fetal diameter with gestational sac. The diameter is compared through the sum of pixel fetal images horizontally and vertically based on the above equation. Figure 3.3 below is an illustration of the integral projection method.

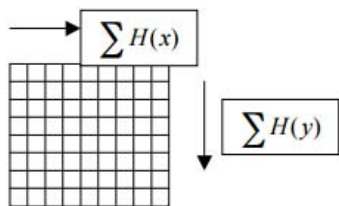



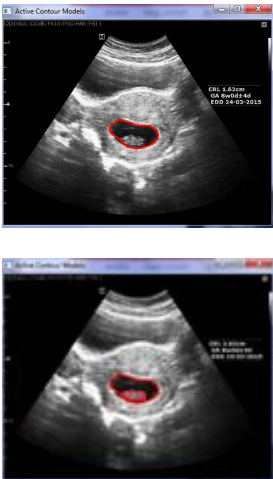

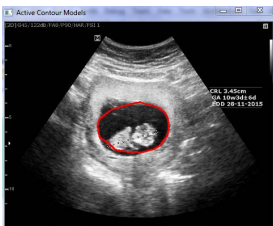
Fig 3.3 Illustration of integral projection method

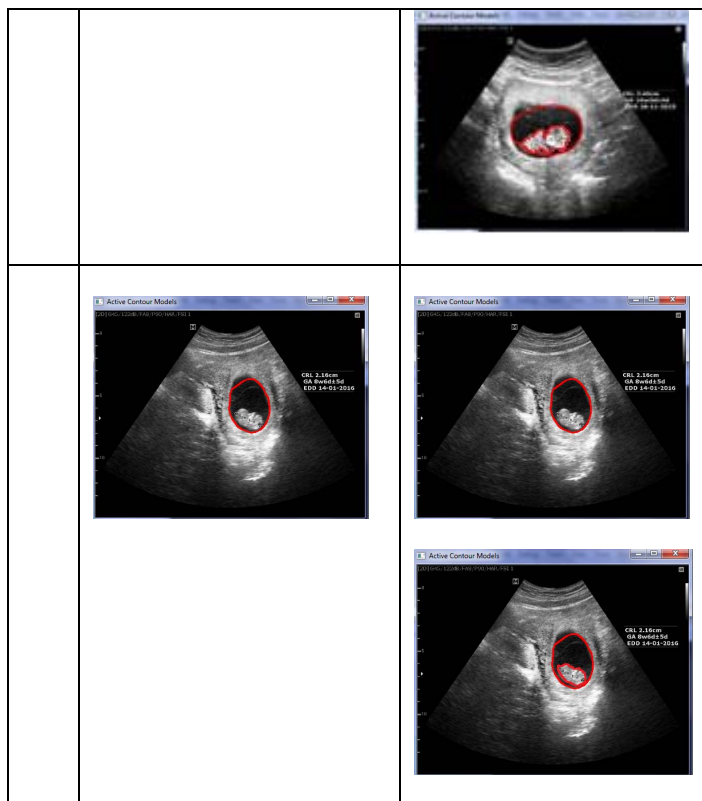IV. EXPERIMENTS AND DISCUSSION

A. Fetal Segmentation Stage and Pregnancy Pouch

After marking the processing area, the next step is to segment the fetus and gestational sac from the fetal ultrasound image. The method used for this segmentation process is the active contours models method.

Table 4.1 The result of segmentation using Active Contours Models method

No	Input	Output
	Grayscale	Active Contours Models
		
		



B. Fetal Long Measurement Stage



Fig 4.1 Measurement of fetal length (a) 0.96 cm, (b) 1.79 cm, (c) 2.65 cm

Based on Figure 4.1 it can be seen that Figure 4.9 (c) has the longest value, which is used as the fetal length. Table 4.4 shows the results of fetal length measurements.

Table 4.2 Fetal Length Measurement Results

Fetal Input	The measurement result (cm)
j01.bmp	2.13 cm
j02.bmp	1.31 cm
j03.bmp	1.59 cm
j04.bmp	2.65 cm
j05.bmp	3.86 cm
j06.bmp	2.24 cm
j07.bmp	1.94 cm
j08.bmp	3.2 cm
j10.bmp	2.45 cm
j11.bmp	1.55 cm

C. Trial for Healthy Fetus

At this stage a healthy fetus is tested. A healthy fetus will be measured in length to get pregnant. Then this gestational age compared to gestational age is calculated manually

through the calculation of the first day of last menstruation (HPHT). Table 4.2 shows the ratio of length to healthy fetuses.

Table 4.2 Long Comparison Table on Healthy Fetus

Input	Fetal length reference	Fetal length measured	Fetal length difference	Error length difference
J01.bmp	2.03 cm	2.13 cm	0.1 cm	4.9 %
J03.bmp	1.73 cm	1.59 cm	0.14 cm	8.09 %
J04.bmp	2.60 cm	2.65 cm	0.05 cm	1.92 %
J05.bmp	3.83 cm	3.86 cm	0.03 cm	0.78 %
J08.bmp	3.45 cm	3.2 cm	0.25 cm	7.24 %
J13.bmp	4.25 cm	4.59 cm	0.34 cm	8 %
J14.bmp	5.23 cm	5.18 cm	0.05 cm	0.95 %
J16.bmp	1.38 cm	1.25 cm	0.13 cm	9.42 %
Average error measurement				5.16 %

REFERENCES

- [1] Gustavo Carneiro, Bogdan Georgescu, Sara Good, Dorin Comainiu. *Detection of Fetal Anatomies from Ultrasound Images using a Constrained Probabilistic Boosting Tree*.
- [2] Chitresh Bhushan. 2009. *Ultrasound Image Segmentation*. Kharagpur, India
- [3] Mohammad Talebi, Ahamd Ayatollahi, Ali Kermani. 2010. *Medical Ultrasound Image Segmentation Using Genetic Active Contour*. Tehran, Iran.
- [4] Sonia Dahdouh, Antoine Serrurier, Gilles Grange, Elsa D.A., Isabelle Bloch. 2014. *Segmentation of Fetal Envelope from 3D Ultrasound Images based on Pixel Intensity Statistical Distribution and Shape Priors*. Paris, France.
- [5] Adhi Pribadi, Johannes C. Mose, Firman F.W. 2011. *Ultrasonografi Obstetri & Ginekologi*. Sagung Seto.
- [6] A Dwi Puspitasari, Handayani Tjandrasa. 2011. *Deteksi Kepala Janin pada Gambar USG Menggunakan Fuzzy C-Means (FCM) dengan Informasi Spasial dan Iterative Randomized Hough Transform (IRHT)*. Surabaya, Indonesia.
- [7] J.Nithya. 2009. *Detection of Intrauterine Growth Retardation Using Fetal Abdominal Circumference*. Tiruchengode, Tamilnadu, India.
- [8] Sanjaya Shankar Tripathy. 2009. *Automatic Health monitoring of Fetus from Ultrasound Images using Level Set Algorithm*. Tamilnadu, India.
- [9] Riyanto Sigit ST.M.Kom,Ph.D (2014). *Segmentasi Imej Untuk Video Ekokardiografi Menggunakan Persamaan Segitiga*, Fakultas Kejuteraan Dan Alam Bina Universiti